

# Ligasure™ Seals Small Lymphatic Vessels as Comparably Well as Hem-o-lok® Clips

Ligasure™ Küçük Lenfatik Damarları Hem-o-lok® Klipsleri Kadar İyi Kapatmaktadır

© Dwayne Chang<sup>1</sup>, © Isaac Thyer<sup>2,3</sup>

<sup>1</sup>Hollywood Private Hospital, Clinic of Urology, Nedlands, Australia

<sup>2</sup>Royal Perth Hospital, Clinic of Urology, Perth, Australia

<sup>3</sup>Fremantle Hospital, Clinic of Urology, Fremantle, Australia

## What's known on the subject? and What does the study add?

Previous studies have shown that Ligasure™ (LS) can seal large lymphatics such as in axillary node dissection. However, no study has directly shown that LS seals small lymphatic vessels. This study compared LS with a standard sealing technique (Hem-o-lok®) in sealing small lymphatics vessels in a canine ex vivo spermatic cord model.

## Abstract

**Objective:** The purpose of this study is to compare small lymphatic vessel sealing using Ligasure™ (LS) and Hem-o-lok® (HML) clips in an ex vivo canine spermatic cord model.

**Materials and Methods:** Canine testes with spermatic cord attached were harvested. By random distribution, the spermatic cord of each testis was either (i) sealed with LS, (ii) clipped with one HML clip, or (iii) had no intervention. The testis was then injected with a Patent Blue V dye solution. At 5 minutes and 12 hours after injection, the distal spermatic cord was inspected for macroscopically visible dye. One random spermatic cord from each of the LS and HML cohorts free of macroscopic evidence of dye was examined using the frozen section histology of the cross sections proximal and distal to the intervention site to detect the microscopic presence of dye.

**Results:** During the study period, 18 canine testes were harvested. After randomization, five, six, and seven testes were included in the control, HML, and LS groups, respectively. In the control group, all 5 testes had leaked blue dye from the cut end of the spermatic cord at 5 minutes. Further, in the HML group, dye was macroscopically visible distal to the intervention site (intervention failure) in 2 out of 6 cases at 5 minutes. In the LS group, 2 out of 7 testes had leaked blue dye at 5 minutes. All testes that did not fail at 5 minutes also did not fail at 12 hours in both LS and HML groups.

**Conclusion:** LS is an effective alternative option to HML clips to seal small lymphatic vessels.

**Keywords:** Diathermy, Lymphedema, Lymph nodes, Surgical instruments

## Öz

**Amaç:** Bu çalışmada, bir ex vivo köpek spermatik kord modelinde, Ligasure™ (LS) ve Hem-o-lok® (HML) klipslerinin küçük lenfatik damar kapatma özellikleri karşılaştırılmıştır.

**Gereç ve Yöntem:** Spermatik kordu bağlanmış köpek testisleri toplandı. Rastgele dağıtım yoluyla, her testisin spermatik kordu ya (i) LS ile kapatıldı, (ii) ya bir HML klipsi ile klipslendi ya da (iii) spermatik korda müdahale edilmedi. Testislere daha sonra Patent Blue V boya solüsyonu enjekte edildi. Enjeksiyondan 5 dakika sonra ve 12 saat sonra distal spermatik kord makroskopik olarak görülebilen boya açısından incelendi. LS ve HML kohortlarının her birinden makroskopik boya kanıtı içermeyen rastgele bir spermatik kord seçildi ve boyanın mikroskopik varlığını saptamak için, müdahale bölgesinin proksimal ve distalinden elde edilen kesitler frozen histolojisi kullanılarak incelendi.

**Bulgular:** Çalışma süresince 18 köpek testisi toplandı. Randomizasyondan sonra sırasıyla beş, altı ve yedi testis kontrol, HML ve LS gruplarına dahil edildi. Kontrol grubundaki 5 testisin tamamı 5. dakikada spermatik kordun kesik ucundan mavi boya sızdırdı. HML grubunda boya, 6 testisin 2'sinde 5. dakikada müdahale sahasının distalinde makroskopik olarak görülebiliyordu (müdahale başarısızlığı). LS grubundaki 7 testisin 2'si 5. dakikada mavi boya sızdırdı. Beşinci dakikada hem LS hem de HML gruplarındaki sızdırmayan testisler 12. saatte de sızdırmadı.

**Correspondence:** Dwayne Chang MD, Hollywood Private Hospital, Clinic of Urology, Nedlands, Australia

**Phone:** (+618) 9346 6000 **E-mail:** Dwayne.Chang@health.wa.gov.au **ORCID-ID:** orcid.org/0000-0003-4268-2479

**Received:** 31.01.2020

**Accepted:** 24.03.2020

**Cite this article as:** Chang D, Thyer I. Ligasure™ Seals Small Lymphatic Vessels as Comparably Well as Hem-o-lok® Clips. J Urol Surg 2020;7(4):281-284.



**Sonuç:** LS, küçük lenfatik damarları kapatmada HML klipslerinin etkili bir alternatifidir.

**Anahtar Kelimeler:** Diyatermi, Lenfödem, Lenf düğümleri, Cerrahi aletler

## Introduction

Ligasure™ [Medtronic, Minnesota, USA (LS)] is a surgical tool with a hemostatic function that seals blood vessels up to 7 mm in diameter by fusing collagen and elastin in the vascular walls using pressure and bipolar energy. Medical literature studies recorded burst pressures of blood vessels sealed with LS that were well above physiologic intraluminal pressures (1–3). Medtronic claims that the vessel seal function of LS also extends to lymphatic vessels and that LS has been shown to seal large lymphatic vessels (4,5). Similarly, LS was associated with a reduced incidence of lymphedema in penile cancer lymph node dissection and substantially reduced drain output after axillary lymph node dissection (6,7). However, studies have yet to provide direct evidence of effective LS sealing of small lymphatic vessels. Moreover, small lymphatic vessels have lower amounts of collagen and elastin in the vascular walls than in large lymphatic vessels for LS to fuse, which can affect its efficacy. Thus, the purpose of this study was to compare LS with the standard sealing technique [Extra-Large Hem-o-lok® (HML) Polymer Locking Ligation System, Catalogue ID 544250, Weck®, Teleflex Inc., Pennsylvania, USA] in the development of effective seals for small lymphatic vessels in a canine *ex vivo* spermatic cord model.

## Materials and Methods

Canine testes were obtained by local veterinarians from dogs that were booked for elective castration. These castrations were pre-booked and performed for reasons unrelated to this study and since these testes were destined to be disposed of anyway, ethics approval for their use in this study was not obtained. In addition, 18 canine testes from 9 dogs were collected over a span of 8 weeks, with each spermatic cord still attached. The veterinarian used scissors to divide the spermatic cord at the time of removal to maintain normal tissue structure. The collected testes were then examined within 1 hour of collection. The spermatic cord of each testis was randomized to either (i) diathermy with LS, (ii) clip with a single HML (Catalogue ID 544250, Weck®), or (iii) no intervention (control group). Further, the intervention was conducted in the LS and HML groups at approximately the halfway point of the remaining spermatic cord. Simple randomization was performed using a random integer generator to generate 18 random integers, with each integer having a value between 1 and 3 (8). Patent Blue V dye solution was then injected deep into the parenchyma of all testes at a similar location on the anterior/anti-epididymal surface of

each testicle using a 23-gauge hypodermic needle. The volume of dye administered differed depending on the relative size of each testicle, ranging from 0.25 mL for very small testes, 0.5 mL for small testes, 0.75 mL for medium testes, and 1.0 mL for large testes. The needle was then attached to an intravenous fluid giving set attached to a 0.9% saline bag hung at a height of 10 cm above the testicle to simulate physiologic lymphatic pressure. Each testicle and spermatic cord specimen were then left lying flat on a horizontal surface (Figure 1). The time of injection was recorded, and checking for blue dye leakage from the cut end of the spermatic cord was done at 5 minutes after the injection of the dye and recorded and the specimen disposed of. If no leakage of blue dye was observed, the specimen was left in place, and a further observation for the leakage of blue dye was made 12 hours later. From the group that did not show a leakage of blue dye at 12 hours, a random sample from each of the LS and HML clip groups was then selected for a frozen section microscopic analysis of the spermatic cord by an anatomical pathologist to detect the presence of blue dye from the cross sections of both immediate sides of the intervention site.

## Statistical Analysis

Descriptive statistics were used to describe the data in percentages (Table 1).

## Results

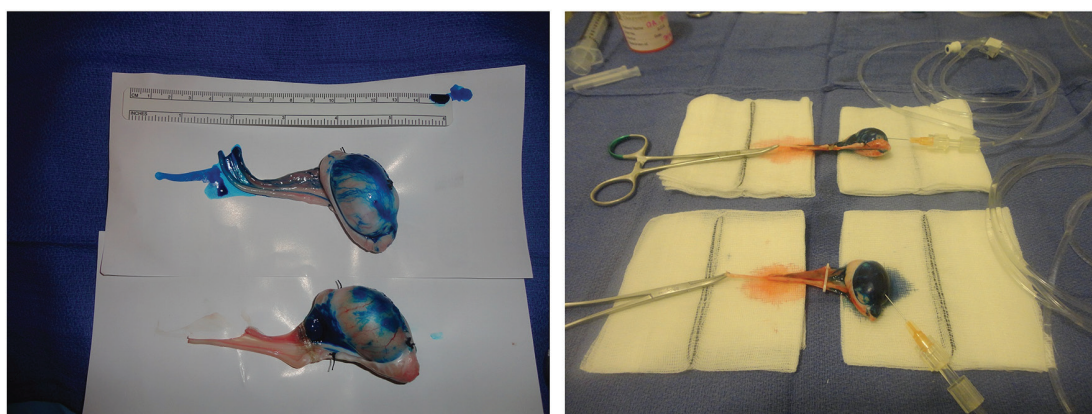
After randomization, five, six, and seven testes were included in the control, HML, and LS groups, respectively. Further, the sizes of the testes differed within each group. The mean volume of dye injected was 0.5 mL in both the LS and HML clip groups and 0.7 mL in the control group (ranging from 0.25 mL to 1.0 mL). In the control group, the five testes showed a leakage of the blue dye from the cut end of the spermatic cord at the 5-minute mark (failure rate 100.0%), and so none was left for observation at 12 hours (Table 1). On the other hand, in the HML clip group, two out of six testes had leaked blue dye at the 5-minute mark. The remaining four testes showed no leakage of blue dye from the spermatic cord at 12 hours, resulting in an overall failure rate of 33.3% (Table 1). Additionally, two of the seven testes in the LS group showed a leakage of blue dye from the spermatic cord at the 5-minute mark. At the 12-hour mark, the remaining five testes showed no leakage of blue dye from the spermatic cord; thus, the overall failure rate was 28.6% (Table 1).

One random testicle free of blue dye leakage at 12 hours was selected from each of the LS and HML clip groups. In the

**Table 1. Rates of blue dye leakage from spermatic cord observed at 5 minutes and 12 hours after administration to the testes.**

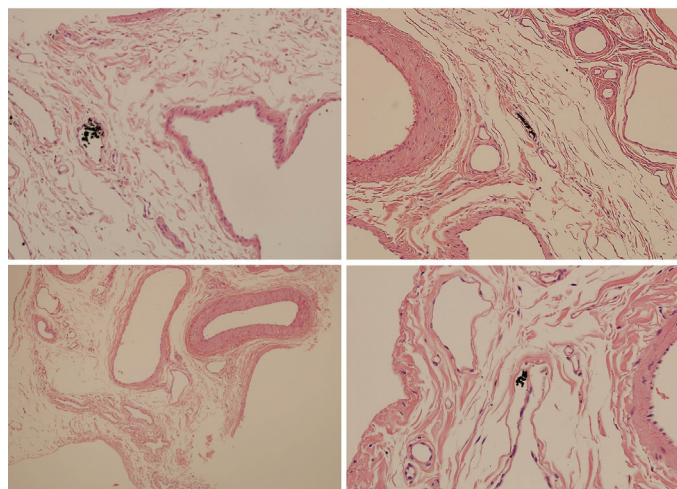
	Lymphatic leakage observed (presence of dye from spermatic cord)		
	5 minutes	12 hours (for testes with no leakage at 5 minutes)	Overall failure rate
Control	5 of 5 (100.0%)	N/A*	5 of 5 (100.0%)
Hem-o-lok® clip	2 of 6 (33.3%)	0 of 4 (0%)	2 of 6 (33.3%)
Ligasure™	2 of 7 (28.6%)	0 of 5 (0%)	2 of 7 (28.6%)
Total	18	9	18

\*Note: N/A, not applicable to observe at 12 hours because each control specimen already had dye leakage observed at 5 minutes



**Figure 1.** Experimental tissue model. Canine spermatic cords were sealed with LS, clipped with an HML, or left without intervention (control group). Blue dye was injected into each testis to test for lymphatic patency

LS: Ligasure™, HML: Hem-o-lok®



**Figure 2.** Under x20 microscopic examination, dye could be observed in the proximal lymphatic vessels (testis side) for both LS (top left) and HML clip (top right) groups. No dye could be seen in the lymphatic vessels distal to the LS seal site (bottom left). However, there was a microscopic focus of dye within the lymphatic vessels seen distal to the HML clip (bottom right)

LS: Ligasure™, HML: Hem-o-lok®

microscopic analysis (Figure 2), the spermatic cords proximal to the LS diathermy or HML clip sites (on the testis side) indicated only the presence of blue dye in the lymphatic vessels. Similarly, no blue dye was found in the lymphatic vessels distal to the LS

diathermy site. However, a microscopic focus of blue dye was present inside the lymphatic vessels at the distance to the HML clip site.

## Discussion

The entire control group had dye leakage at 5 minutes, thus demonstrating the patency of the lymphatic vessels and suitability of this *ex vivo* experimental model to test the relative effectiveness of LS and HML in sealing small lymphatic vessels.

Compared to HML clips, the use of LS on canine spermatic cords was associated with a lower overall macroscopic failure rate of lymphatic blue dye leakage distal to the intervention site. Furthermore, on a microscopic examination of specimens that did not fail macroscopically, no blue dye was seen in the LS spermatic cord in the lymphatic vessels distal to the intervention site, whereas blue dye was seen distal to the HML clip. The difference in failure rate between the two groups was insignificant, and the sample size was too small to analyze this result for statistical significance. However, this result is compelling and helps establish a basis to accept Medtronic's claim that LS can seal small lymphatic vessels.

A significant finding was that if either LS or HML clip failed to prevent a macroscopic leak, it was always detected within 5

minutes. Therefore, if fluid accumulation is minimal at the time of in vivo lymph node dissection, then continuous lymphatic leakage is likely to be minimal.

### Study Limitations

The first limitation of this study was the small sample size that restricted the ability to analyze our data for statistical significance. Thus, conventional simple randomization of small sample sizes can still result in unequal distribution of cohorts and baseline characteristics among groups. Second, an *ex vivo* tissue model has inherent drawbacks, including interference with tissue planes and structure during tissue removal from the animal, and thus the physiologic homeostasis of tissue oncotic pressure and tissue integrity would naturally be compromised. To limit the impact, the collected tissue was analyzed within 1 hour upon collection. Finally, the tissue model chosen contains other structures that could have a detrimental impact on the result. Other collagen-rich tissue lies alongside the lymphatic vessels in the spermatic cord, including blood vessels and vas deferens. Consequently, the seal on the small lymphatic vessels seen in this study may be partially due to the presence of these other structures.

### Conclusion

Our study demonstrated comparable efficacy between LS and HML in creating seals on small lymphatic vessels inside the spermatic cords of *ex vivo* canine models. Larger in vivo clinical studies may shed more light on the comparable efficacy of LS against other vessel sealing methods in the current use for lymph node dissection.

### Ethics

**Ethics Committee Approval:** These castrations were pre-booked and performed for reasons unrelated to this study and since these testes were destined to be disposed of anyway, ethics approval for their use in this study was not obtained.

**Informed Consent:** These castrations were pre-booked and performed for reasons unrelated to this study and since these testes were destined to be disposed of anyway.

**Peer-review:** Externally peer-reviewed.

### Authors Contributions

Concept: D.C., I.T., Design: D.C., I.T., Data Collection or Processing: D.C., I.T., Analysis or Interpretation: D.C., I.T., Literature Search: D.C., I.T., Writing: D.C., I.T.

**Conflict of Interest:** No conflict of interest was declared by the authors.

**Financial Disclosure:** The authors declared that this study received no financial support.

### References

1. Carbonell AM, Joels CS, Kercher KW, Matthews BD, Sing RF, Heniford BT. A comparison of laparoscopic bipolar vessel sealing devices in the hemostasis of small-, medium-, and large-sized arteries. *J Laparoendosc Adv Surg Tech A* 2003;13:377–380.
2. Harold KL, Pollinger H, Matthews BD, Kercher KW, Sing RF, Heniford BT. Comparison of ultrasonic energy, bipolar thermal energy, and vascular clips for the hemostasis of small-, medium-, and large-sized arteries. *Surg Endosc* 2003;17:1228–1230.
3. Hruby GW, Marruffo FC, Durak E, Collins SM, Pierorazio P, Humphrey PA, Mansukhani MM, Landman J. Evaluation of surgical energy devices for vessel sealing and peripheral energy spread in a porcine model. *J Urol* 2007;178:2689–2693.
4. Box GN, Lee HJ, Abraham JB, Deane LA, Elchico ER, Abdelshehid CA, Alipanah R, Taylor MB, Andrade L, Edwards RA, Borin JF, McDougall EM, Clayman RV. Comparative study of in vivo lymphatic sealing capability of the porcine thoracic duct using laparoscopic dissection devices. *J Urol* 2009;181:387–391.
5. Novitsky YW, Rosen MJ, Harrell AG, Sing RF, Kercher KW, Heniford BT. Evaluation of the efficacy of the electrosurgical bipolar vessel sealer (LigaSure) devices in sealing lymphatic vessels. *Surg Innov* 2005;12:155–160.
6. Gallo Rolania FJ, Beneitez Alvarez ME, Izquierdo Garcia FM. The role of inguinal lymphadenectomy in epidermoid carcinoma of the penis. Use of Ligasure and analysis of the results. *Arch Esp Urol* 2002;55:535–538.
7. Cortadellas T, Córdoba O, Espinosa-Bravo M, Mendoza-Santin C, Rodríguez-Fernández J, Esgueva A, Alvarez-Vinuesa M, Rubio IT, Xercavins J. Electrothermal bipolar vessel sealing system in axillary dissection: a prospective randomized clinical study. *Int J Surg* 2011;9:636–640.
8. RANDOM.ORG. Ireland: Randomness and Integrity Services Ltd. 2012. Random Integer Generator. <https://www.random.org/integers/>