

# Management of Rectourethral Fistula following a Gunshot Injury with Gracilis Flap: A Case Report

Ateşli Silah Yaralanması Sonrası Gelişen Rektoüretal Fistülün Gracilis Flep ile Onarımı:  
Olgu Sunumu

Mutlu Değer<sup>1</sup>, Fatih Gökalp<sup>1</sup>, Eyüphan Gencel<sup>2</sup>, Erkan Demir<sup>1</sup>, Zühtü Tansuğ<sup>1</sup>

<sup>1</sup>Çukurova University Faculty of Medicine, Department of Urology, Adana, Türkiye

<sup>2</sup>Çukurova University Faculty of Medicine, Department of Plastic Reconstructive and Aesthetic Surgery, Adana, Türkiye

## Abstract

Rectourethral fistulas are uncommon and can be classified as congenital or acquired. We present a case of rectourethral fistula following a shotgun injury and describe a surgical method of closing poorly healing defects between the urethra and rectum by means of a muscular flap of the gracilis muscle (GM). A 20-year-old man underwent laparotomy and colostomy for gunshot trauma. In postoperative first week, the patient began complaining of urine coming from the rectum. Retrograde urethrography revealed a fistulous opening connecting the prostatic urethra and the rectum. The transperineal approach with a GM flap interposition is currently the most commonly used method and one of the effective procedures for treating complex fistulae. Morbidity after a GM flap interposition is known to be low. GM transposition is a useful and effective method for the treatment of rectourethral fistula.

**Keywords:** Gunshot injury, rectourethral fistula, gracilis flap

## Öz

Rektoüretal fistüller nadiren görülmektedir ve konjenital veya edinilmiş olarak sınıflandırılabilir. Biz, ateşli silah yaralanması sonrası gelişen rektoüretal fistüllü olguyu ve zor iyileşen üretra ve rektum arasındaki defekt için gracilis flep kullanılarak yapılan cerrahi tekniği sunmaktayız. Yirmi yaşında erkek hastaya ateşli silah yaralanması sonrası laparotomi ve kolostomi açılması uygulanmıştı. Postoperatif ilk haftada, hasta makattan idrar geldiğini tarifledi. Bunun üzerine çekilen retrograd üretrografi prostatik üretra ve rektum arasında fistül olduğu gösterildi. Hastaya transperineal yaklaşımla gracilis flep interpozisyonu kullanılarak rektoüretal fistül onarımı uygulandı. Gracilis kas flep interpozisyonu transperineal yaklaşım halen en çok kullanılan yöntemdir ve kompleks fistüllerin tedavisinde tercih edilen prosedürlerden biridir. Gracilis kas flep interpozisyonu sonrası morbidite az görülür. Bu yöntem rektoüretal fistüllü olguların tedavisinde kullanılabilir ve etkili bir yöntemdir.

**Anahtar Kelimeler:** Ateşli silah yaralanması, rektoüretal fistül, gracilis flep

## Introduction

Rectourethral fistulas (RUFs) are uncommon and can be classified as congenital or acquired. Acquired RUFs are the result of surgical complications, pelvic irradiation or ablative treatments, trauma, chronic infection, or malignancy (1). Spontaneous closure of such fistulas is rare and reconstructive procedures are usually performed. Many surgical approaches have been described: transabdominal, abdominoperineal, transperineal, transanal, transsphincteric (i.e., York-Mason), and transsacral (2).

We present a case of rectourethral fistula following a gunshot injury treated by the use of gracilis musculocutaneous flap.

## Case Presentation

A 20-year-old man underwent laparotomy and colostomy for gunshot trauma. In the postoperative first week, the patient began complaining of urine coming from the rectum after Foley catheter was removed. The patient was followed up with suprapubic cystostomy catheter for three months.

**Correspondence:** Mutlu Değer MD, Çukurova University Faculty of Medicine, Department of Urology, Adana, Türkiye

**Phone:** +90 530 011 30 59 **E-mail:** drmutludeger@gmail.com

**Received:** 30.06.2015

**Accepted:** 11.02.2016

**Cite this article as:** Değer M, Gökalp F, Gencel E, Demir E, Tansuğ Z. Management of Rectourethral Fistula following a Gunshot Injury with Gracilis Flap: A Case Report. J Urol Surg 2017;4:23-25.

©Copyright 2017 by the Association of Urological Surgery / Journal of Urological Surgery published by Galenos Publishing House.



Retrograde urethrography (RUG) revealed a fistulous opening connecting the prostatic urethra to the rectum and computed tomography showed a fistula tract. A urethroscopy was done to demonstrate the fistula and at prostatic urethra a 3 cm fistulous communication with the rectum. The bladder was grossly normal. As definitive treatment for the fistula we performed rectourethral fistula repair with gracilis flap (Figure 1). He had an indwelling urethral catheter for 2 weeks. After catheter removal, he voided well. Post-operative RUG revealed well-healed prostatic urethral anastomosis. Colostomy was closed after surgery.

### Technique

The gracilis is a superficial muscle on the medial side of the thigh. The technique of gracilis muscle (GM) transposition for repairing rectourethral fistula has been previously reported (3). The patient is placed in the modified lithotomy position with the thigh abducted. The skin incision is made right along with the inner part of the thigh. GM always located over proximal 10 cm of a line between pubic tubercle and the medial upper surface of the tibia. GM is mobilized and released from its insertion that near the tibial plateau. By protecting dominant vessels which can alone nourish entire muscle, segmental arteries are cauterized. In the process the main neurovascular bundle, 8-10 cm below the pubic tubercle, is described and preserved. A subcutaneous tunnel is then made towards the perineum. By protecting of the little muscle cuff, an island flap is released from the proximal part of muscle origin. So the pedicle of the muscle is saved from shearing and stretching. The flap rotate into a subcutaneous tunnel towards to perineum without kinking. The incision are closed with suction drain. A perineal λ-shaped skin incision was applied between the anus and scrotum and is deepened in the space between the urethra and the rectum for the correction of the fistula. The remainder of the urethra not involved in the fistula is identified and protected by the help of a large urinary

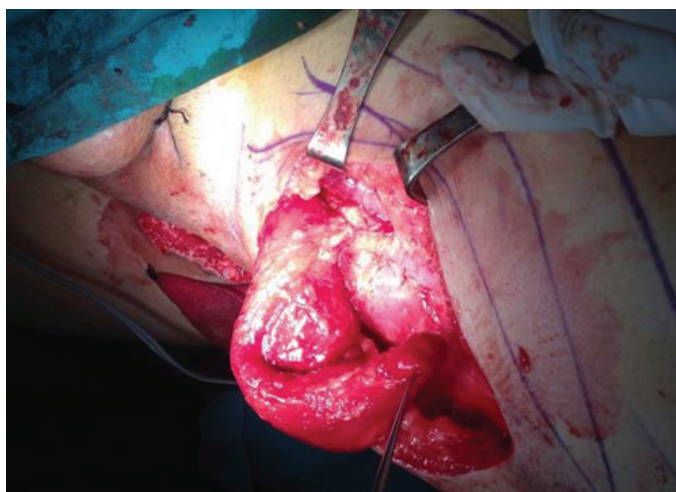


Figure 1. Transposition of gracilis muscle

bladder catheter. The dissection is made to divide the fistula tract and reach cephalad to non-inflamed tissue. Primarily the rectal defect is closed in two layers then urethral defect is closed with interrupted absorbable sutures over the indwelling catheter. The GM is moved to the area between the rectum and the urethra by the subcutaneous tunnel between the perineum and thigh is done through the perineal side (Figure 2). Four to six polydioxane sutures are applied at the apex of the incision to hold the muscle in place. Before skin closure, a small suction drain is placed in the perineal wound.

### Discussion

RUF is seen rarely and has varied etiologic factors: including iatrogenic, neoplastic or traumatic. Traumatic RUFs are frequently observable in wartime injuries (4) and continue with extensive urethral injury that leads to extensive stricture. Traumatic RUF can cause forcing matters in surgical reconstruction. As this condition is very rare, no single procedure has been proven most effective and become the technique of choice (4).

Diagnosis is based on history, physical examination, and radiologic tests. Symptoms may include fecaluria, pneumaturia, hematuria, urinary tract infection, nausea, vomiting, and fever. Digital rectal examination often permits palpation of the fistula tract along the anterior rectal wall. Voiding cystourethrography or RUG usually provide a definitive diagnosis of RUF. Cystoscopy and sigmoidoscopy visualize the fistula tract and provide a mechanism for biopsy. Biopsies should be done if there is concern for malignancy.

In general, conservative management can be attempted by using fecal diversion and/or urinary diversion (ie, urethral catheter and/or suprapubic catheter) for small (<2 cm), nonirradiated RUFs in patients who do not have sepsis. However, most RUFs do not respond to conservative treatment and require surgical repair (5).

Many surgical approaches have been described: transabdominal, abdominoperineal, transperineal, transanal, transsphincteric, and transsacral (2). The transperineal approach with a GM flap interposition is recently the most commonly applied method

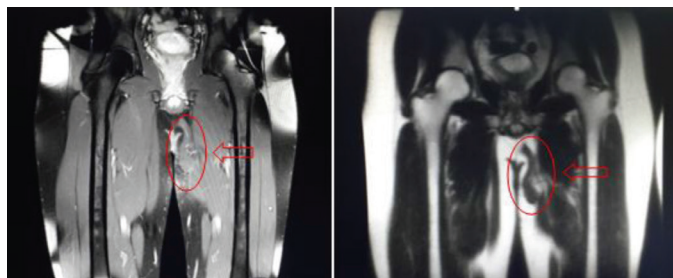


Figure 2. Postoperative magnetic resonance and gracilis muscle

and the efficient procedures for treating complex fistulae. The GM has been applied as a rotation flap or for different purposes without a significant effect on lower limb strength and range of motion. Ryan et al. (3) described the use of the gracilis transposition for the treatment of rectourethral fistula in 1979. By depending on three cases which lasted over a period of 15 years and had a 100% success rate, Nyam and Pemberton (6) reported that GM transposition had better success rate than did other types of repair of rectourethral fistula. The largest series of 53 rectovaginal fistulas and RUFs with GM interposition was suggested by Wexner et al. (7) and the overall initial 70% success rate was obtained then the final success rate of seven repeated GM transpositions was 87%.

Due to fact that it supplies good exposure of the rectum, urethra and the neck of the bladder, urethral pathologies can be operated on at the same time through the transperineal route thereby allowing distal urethral mobilization associated in this method (8). However, morbidity of a GM flap interposition is known to be rare, urethral stricture and urinary incontinence can appear as complications.

GM transposition is a useful and effective method for the treatment of rectourethral fistula causing by gunshot. This procedure is associated with low morbidity and high success.

### Ethics

Informed Consent: It was taken.

Peer-review: External and internal peer-reviewed.

### Authorship Contributions

Surgical and Medical Practices: Zühtü Tansuğ, Erkan Demir, Mutlu Değer, Eyüphan Gencel, Concept: Mutlu Değer, Fatih

Gökalp, Design: Mutlu Değer, Fatih Gökalp, Data Collection or Processing: Mutlu Değer, Fatih Gökalp, Analysis or Interpretation: Eyüphan Gencel, Literature Search: Mutlu Değer, Fatih Gökalp, Writing: Mutlu Değer, Fatih Gökalp.

Conflict of Interest: No conflict of interest was declared by the authors.

Financial Disclosure: The authors declared that this study received no financial support.

### References

1. Moss RL, Ryan JA Jr. Management of enterovesical fistulas. *Am J Surg* 1990;159:514-517.
2. Remzi FH, El Gazzaz G, Kiran RP, Kirat HT, Fazio VW. Outcomes following Turnbull-Cutait abdominoperineal pull-through compared with coloanal anastomosis. *Br J Surg* 2009;96:424-429.
3. Ryan JA, Beebe HG, Gibbons RP. Gracilis muscle flap for closure of rectourethral fistula. *J Urol* 1979;122:124-125.
4. Al-Ali M, Kashmoula D, Saoud IJ. Experience with 30 posttraumatic rectourethral fistulas: Presentation of posterior transsphincteric anterior rectal wall advancement. *J Urol* 1997;158:421-424.
5. Nyam DC, Pemberton JH. Long-term results of lateral internal sphincterotomy for chronic anal fissure with particular reference to incidence of fecal incontinence. *Dis Colon Rectum* 1999;42:1306-1310.
6. Nyam DC, Pemberton JH. Management of iatrogenic rectourethral fistula. *Dis Colon Rectum* 1999;42:994-997.
7. Wexner SD, Ruiz DE, Genua J, Nogueras JJ, Weiss EG, Zmora O. Gracilis muscle interposition for the treatment of rectourethral, rectovaginal, and pouch-vaginal fistulas: results in 53 patients. *Ann Surg* 2008;248:39-43.
8. Choi JH, Jeon BG, Choi SG, Han EC, Ha HK, Oh HK, Choe EK, Moon SH, Ryoo SB, Park KJ. Rectourethral fistula: systemic review of and experiences with various surgical treatment methods. *Ann Coloproctol* 2014;30:35-41.